

Idiopathic Unilateral Monoarticular Hemosiderotic Synovitis of Knee Joint Mimicking Pigmented Villonodular Synovitis – an Unusual Case

Deshmukh S. D.* , Siddhi Gaurish Sinai Khandeparkar** , Khadilkar M. S.*** , Shah Nakul**** , Naik Pooja***** , Giakwad Yogesh*****

*Professor, **Associate Professor, ****MD Pathology, Department of Pathology, Smt Kashibai Navale Medical College, Pune(Maharashtra) India.*** Professor and head, **** Professor, *****Assistant professor, Department of Orthopaedics, Smt Kashibai Navale Medical College, Pune(Maharashtra) India

Introduction

Hemosiderotic synovitis (HS) is a reactive condition caused by excessive and repeated bleeding into joint where the synovium turns rusty due to accumulation of hemosiderin pigment in the stratum synoviale [1–4]. The main differential of HS is pigmented villonodular synovitis (PVNS) which is a neoplastic condition and needs aggressive treatment. It is very difficult to differentiate HS from PVNS clinically. According to some reports, about 40% cases of HS are misdiagnosed as PVNS [1]. Histopathology plays an important role in accurate diagnosis of HS, which surely helps the surgeon to decide proper line of management.

We encountered a case of unilateral synovitis in a young non hemophilic female who was diagnosed clinically as well radiologically as PVNS and underwent synovectomy. However, histopathological examination has revealed a diagnosis of HS. Since, a preoperative diagnosis by synovial biopsy would have helped in avoidance of a more radical surgery in a young female, and this case is being presented.

Case report

A 19 year old female presented to orthopedics outpatient department with complaints of intermittent

pain and swelling of left knee joint since 5 year duration. Due to this she had discomfort during her routine activities. She had no history of trauma. There was no history of bleeding disorder and family history is also non contributory. General examination was unremarkable. Local examination of knee joint revealed tenderness and restriction of movement. Routine hematological and biochemical laboratory findings were within normal range. Test for rheumatoid factor was also negative.

Magnetic resonance imaging (MRI) showed gross hypertrophy of synovium which was hypointense on T_1 weighted (T_1W) image and hyperintense on T_2 weighted (T_2W) images. Also noted was collection of fluid in supra patellar and patello-femoral bursa

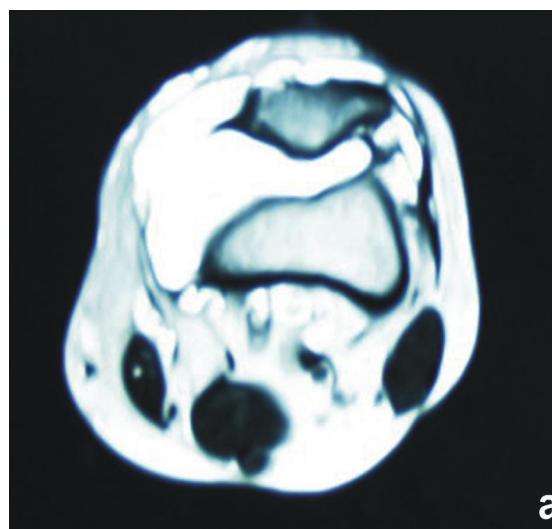


Fig. 1: (a) Axial Transverse W MRI showing hypertrophic and villous proliferation arising from synovial lining

Corresponding Author: Sanjay Digambar Deshmukh, Professor, Department of Pathology, Smt Kashibai Navale Medical College, S.No. 49/1, Off Mumbai - Pune Bypass, Narhe, Pune, Maharashtra- 411041
E-mail: drsanjay123in@yahoo.co.in

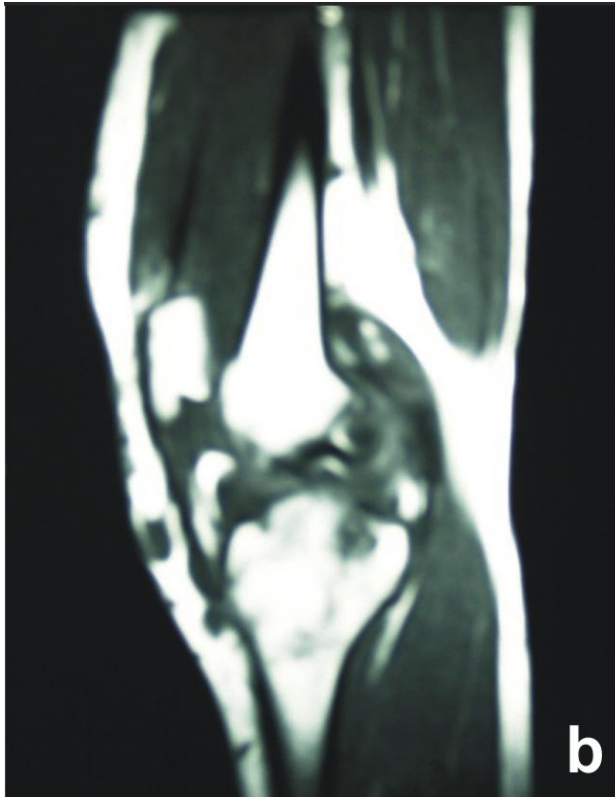


Fig. 1: (b) Sagittal T.W MRI showing hypertrophic synovium

[Fig.1]. With preoperative diagnosis of PVNS, the patient underwent synovectomy. We received a membranous structure, measuring 15'2'0.8cm. Externally it was brownish and granular. Microscopy showed marked papillary hyperplasia of synovial tissue [Fig. 2a]. The hemosiderin granules were confirmed by Prussian blue stain [Fig. 2b]. No areas of solid growth and/or giant cells were seen. Immunohistochemistry revealed a Ki 67 of 2%. With above findings a diagnosis of HS was offered. After

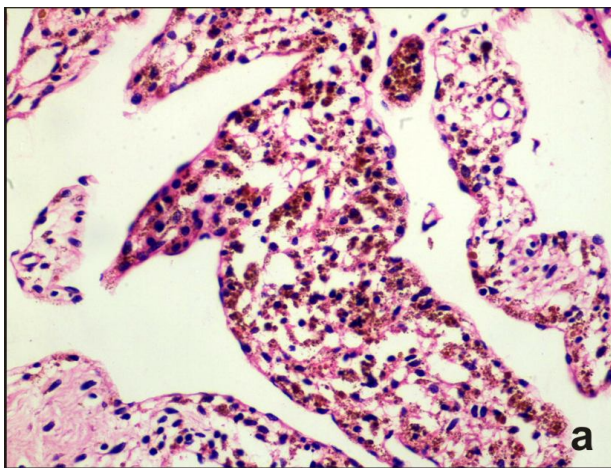


Fig. 2: (a) Surface synovial cells and brown stained intracytoplasmic hemosiderin granules (H&E, 400X)

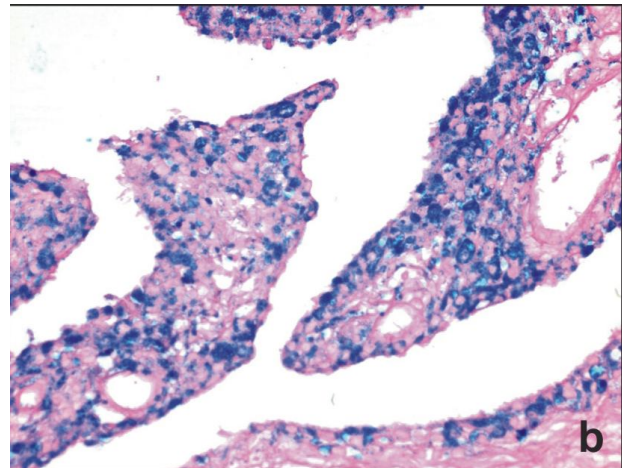


Fig. 2: (b) Special stain microscopic view demonstrating accumulation of iron localized in the superficial synovium. (Prussian blue, 400x)

one year follow up, the patient was well and didn't show any signs of recurrence.

Discussion

HS is characterized by collection of hemosiderin in the synovial tissue secondary to hemarthrosis of joint [4]. Pain and stiffness of joint are the main complaint of patients with HS. Our patient also had similar symptoms. The commonest cause of HS is hemophilia followed by other causes like oral anticoagulants use, trauma, rheumatoid or psoriatic arthritis, osteoarthritis, collagen vascular disease, scurvy, sickle cell anemia, synovial hemangioma and myeloproliferative diseases [5]. In our case these conditions were ruled out by negative family history, laboratory tests and clinical examinations. Also there was no history of any antecedent drug intake. On radiological examination, there is seen gross hypertrophy of synovium which is hypointense on T₁W image and hyperintense T₂W images of MRI. A few authors, have also reported concentric joint space narrowing in HS which was absent in our case [6]. PVNS has similar features on MRI.

In HS, synovial membrane shows rusty brown discoloration due to accumulation of hemosiderin pigment. In early stages, fine villous processes of synovial membrane extend into joint space. Microscopically, the cuboidal, plump, surface synovial cells show presence of hemosiderin granules. Unlike PVNS, larger nodules and thickened papillary fronds are absent in HS. Similar gross and microscopic findings were noted in our case. Absence of mononuclear epithelioid cells, multinucleated osteoclast like giant cells and lipid rich cells in the sub epithelial tissue ruled out PVNS as the cause [1].

In HS, the primary cause should be treated along with the conservative management for local symptoms. On the other side PVNS needs aggressive treatment and radiotherapy. As the joint pain and stiffness are commonly encountered complaints in any joint pathology, synovial biopsy and histopathology play an important role in providing the definitive diagnosis. Progressive joint degeneration can be prevented by early and correct diagnosis of HS, which will help in getting proper treatment, improving the prognosis and decreasing morbidity in the patient.

References

1. Mahendra G, Kliskey K, Athanasou NA, Immunophenotyping distinction between pigmented villonodular synovitis and hemosiderotic synovitis. *J Clin Pathol*. 2010; 63: 75–78
2. Weiss SW, Goldblum JR, Enzinger and Weiss's Soft tissue tumors 5th ed. Philadelphia. Mosby Elsevier. 2008; 769–88
3. Mira JM. The joints In Coulson WF ed. Surgical pathology. Philadelphia, Lippincott 1988; 1499–505.
4. Collins DH, Leeds, England, Hemosiderosis and Hemochromatosis of synovial tissue, *The Journal of Bone and Joint Surgery*. Aug. 1951; 33(3)
5. Yalcin Nadir, Bektaser B, Cicekli O et al, An unusual case of recurrent joint effusions: non-hemophilic hemosiderotic synovitis of the knee. *Acta Orthop Traumatol Turc* 2010; 4(2): 162–165.
6. Abrahams TG, Hughston JC. Pigmented villonodular synovitis. *J. Bone Joint Surg. (Am)* 1987; 69: 942–9.
7. John X, O'Connell MB Pathology of the synovium, *Am J ClinPathol* 2000; 114: 773–784.

Instructions to Authors

Submission to the journal must comply with the Guidelines for Authors.
Non-compliant submission will be returned to the author for correction.

To access the online submission system and for the most up-to-date version of the Guide for Authors please visit:

<http://www.rfppl.co.in>

Technical problems or general questions on publishing with IJPRP are supported by Red Flower Publication Pvt. Ltd's Author Support team (<http://www.rfppl.co.in>)

Alternatively, please contact the Journal's Editorial Office for further assistance.

A Lal
Publication-in-Charge
Indian Journal of Pathology: Research and Practice
Red Flower Publication Pvt. Ltd.
48/41-42, DSIDC, Pocket-II
Mayur Vihar Phase-I
Delhi – 110 091
India

Phone: 91-11-22754205, 45796900, Fax: 91-11-22754205

E-mail: redflowerppl@gmail.com, redflowerppl@vsnl.net

Website: www.rfppl.co.in